

# The retrocondylar retinaculum (Osborne's ligament) and Struther's ligament

## Review of two important osteofibrous structures of the upper limbs.

Kennedy Martínez de Oliveira<sup>1</sup>, Emilyly Dutra Amaral Meggiolaro<sup>1</sup>, Maísa de Fátima Satiro Oliveira<sup>2</sup>, Giuliano Roberto Gonçalves<sup>3</sup>, Valério Landim de Almeida<sup>1</sup>, Leandro Henrique Grecco<sup>4</sup>, Lucas Nogueira Ramos<sup>1</sup>, Éwerton Machado Veloso<sup>1</sup>

### SUMMARY

Many of the musculofascial and osteofibrous structures of the upper limbs, and which are of the normal human structural constituent (pattern), are notably neglected in general anatomical descriptions. Their complex structures, and sometimes controversial or incomplete descriptions, have significant implications in important neurovascular conditions, such as compressive trauma, and those of orthopedic reconstructions. Thus, we objective a detailed study, structural and historical, of the literature, on two of the most important osteofibrous formations - the retrocondylar retinaculum (Osborne's ligament), together with the aponeurosis of the flexor carpi ulnar muscle (Osborne's fascia), and the Struther's ligament in association with the supracondylar process and foramen homonym.

**Keywords** - Ulnar Neuropathies, retrocondylar retinaculum, Struthers, Osborne and supracondylar process.

### *El retináculo retrocondilar (ligamento de Osborne) y el ligamento de Struther*

#### *Revisión de dos importantes estructuras osteofibrosas de los miembros superiores.*

### RESUMEN

Muchas de las estructuras musculofasciales y osteofibrosas de los miembros superiores, y que son del componente estructural humano normal (estándar), se descuidan notablemente en las descripciones anatómicas generales. Sus estructuras complejas, y, por veces, las descripciones controvertidas o incompletas tienen implicaciones significativas para afecciones neurovasculares importantes, como traumatismos por compresión y reconstrucción ortopédica. Por lo tanto, nuestro objetivo es un estudio detallado, estructural e histórico de la literatura sobre dos de las formaciones osteofibrosas más importantes: el retináculo retrocondilar (ligamento de Osborne), junto con la aponeurosis del músculo flexor cubital del carpo (fascia de Osborne) y el ligamento de Struther en asociación con la apófisis supracondílea y foramen homónimo.

**Palabras clave** - Neuropatías Cubitales, retináculo retrocondilar, Struthers, Osborne e proceso supracondilar

### INTRODUCTION

The upper limb is provided with a series of important and capricious paths or restricted pathways of neurovascular conductions which, due to their osteofibrous, fibromuscular and/or musculofascial constitutions, are protagonists of many of the syndromes, principally compressive, of this appendicular segment, as we noticed in

some studies (1-3). In addition, many of these conditions are maximized by various orders of pathologies and of different natures, by proximity, such as fractures, tumor masses and Other expansive processes. However, we observe that in the anatomical descriptions of the literature, in general, these important structures, with significant

1. Federal University of Juiz de Fora, Brazil
2. Federal University of Minas Gerais, Brazil
3. School of Medicine São Leopoldo Mandic, Brazil
4. São Leopoldo Mandic Institute and Research Center, Brazil

**Quote as:** Oliveira K.M, Meggiolaro E.D.A, Oliveira, M.F.S, Gonçalves G.R, Almeida V.L, Grecco L.H, et al. The retrocondylar retinaculum (Osborne's ligament) and Struther's ligament: Review of two important osteofibrous structures of the upper limbs. Rev Peruana de Morfología. 2020; 1(2):21-26. doi:<https://doi.org/10.51343/revperuanamorfologia.421>

**Received:** 31/12/2020; **Accepted:** 25/01/2021; **Online publication:** 09/03/2021

**Corresponding Author:** Kennedy Martínez de Oliveira

Email: [kennedy.martinez@gmail.com](mailto:kennedy.martinez@gmail.com)

Address: Rua Niquelina, 58, apto 702, Belo Horizonte (cep: 30260-100), Minas Gerais, Brasil. Tel. + 55 31 9 9246 0382.

clinical connections, are severely neglected and described with many equivocations. Thus, the most significant topographic conditions of the upper limbs related to different clinical manifestations of neurovascular disturbances are: Costoclavicular Space, Retropeitoral Space, Triangular Space, Quadrangular Space, Triangular Interval, Axillopectoral Muscle (Langer's axillary arch), Brachial Canal (Cruveilhier canal), Radial Nerve Groove (radial nerve canal), Cubital fossa (and its medial and lateral divisions), Aponeurosis Bicipital, Aponeurosis of the Flexor carpi ulnaris muscle (Osborne's Fascia), Proximal Ulnar Tunnel, Arcade of Struthers, Struther's Ligament, Supracondylar foramen, Arcade of Frohse, Teres Pronator Muscle, Flexor Digitorum Superficialis Muscle Arch, Gantzer's Muscle Variants, Parona's Space, Distal Ulnar Tunnel, Anatomical Snuff Box, Guyon's Canal, Carpal Tunnel and the Extensor Tendon Compartments of the Wrist. In addition to the Hiatus or Interescalene Interval and the Scalenovertebral Space which, due to its intimate structural relations and clinical repercussions with the upper limb, we consider associated from this segment.

## MATERIAL AND METHODS

Narrative literature review conducted in PubMed, Scielo and Lilacs databases, using descriptors such as "ulnar neuropathy" and "Struthers", indexed in Medical Subject Heading, using the Boolean AND operator to cross-reference terms between each other and their correspondents in Portuguese and Spanish. The works were included, without temporal space delimitation, with significant contributions in the anatomical descriptions of the structures under studies. We also refer to the books of higher representativeness in topographic anatomy and anatomical variations.

## DISCUSSION

***Retrocondylar Retinaculum:*** (*Osborne Ligament*) and Aponeurosis of the flexor carpi ulnaris muscle (*Osborne fascia*)

Synonyms for the retrocondylar retinaculum (or the popular Osborne ligament) are vast and can cause confusion because many of the authors do not distinguish with sufficient precision all local fibromuscular occurrences, including highly variable

ones. Thus, among the various denominations three are distinguished as alternatives to the eponymic expression Osborne's fascia - Cubital Tunnel Retinaculum, Retro-cubital Retinaculum and Retrocondylar Retinaculum (4-9). We opted for the denomination retrocondylar retinaculum for the major anatomical proximity. The clinical importance, considering the location, is notorious for the neuropathic possibilities of the ulnar nerve of the compressive type (6, 8). However, many authors confuse the fibrous portion of the proximal ulnar tunnel, the Osborne's fascia and the retrocondylar retinaculum (Osborne's ligament), designating them by equal, without characterizing them for their distinct anatomical natures. In addition, there is the fact that the retrocondylar retinaculum is considered, in some cases, by apposition, with a muscle variant called "anconeus epitrochlearis" described by Le Double (1897) (10) and which was also called by Testut, in 1893 (11), as the "épitrochléo-cubital" muscle. This occurs principally when muscle formation is scarce (of well-spaced bundles) or due to insufficiencies in dissections. This muscle formation originates (proximal insertion) from the posterior face of the medial epicondyle and is inserted (distal insertion) in the olecranon of the ulna (12). Le Double (1897) (10) recognizes the "fibrous arch" (the retrocondylar retinaculum) as a distinct fibrous formation between the medial epicondyle and the olecranon of the ulna, independent of the muscle variant "anconeus epitrochlearis", but the "fibrous arch", according to the author, can be perceived as a remnant of the muscle structure variant and replacing it, perspective corroborated by some authors (7, 13). Granger et al. (2017) (5) reported that the Osborne ligament (retrocondylar retinaculum), in the view of some authors, is the replacement of the "anconeus epitrochlearis" muscle or an enhancement of this muscle, as in the conclusions of Dellon (1986) (13). The incidence of this muscle is variable (14), report 27.2% of findings of the "anconeus epitrochlearis" muscle in surgical cases related to idiopathic ulnar compressive syndrome. Dellon (1986) (13) reported 12% of "anconeus epitrochlearis" muscle formations in his dissections and all of them innervated by ulnar nerve branches, in addition to the relationship with a projection of the medial head of the triceps brachii muscle. As for locations and anatomical

characteristics, the retrocondylar retinaculum is a subcutaneous fibrous connection band, of notable density, which is disposed of from the apical portion of the medial epicondyle to, in general, the dorsal-medial part of the ulnar olecranon. The retrocondylar retinaculum thus produces a tunnel in the proximal aspect of most part of the epitrochleo-olecranon groove or retrocondylar groove, constituting its roof and having, in a diametrical position, in the floor of this tunnel, the posterior division of the ulnar collateral ligament (medial collateral ligament of the elbow). With respect to the neurovascular content, we observed, in depth to the retrocondylar retinaculum, the ulnar nerve and accompanying vessels - superior collateral ulnar and posterior inferior recurrent ulnar. The retrocondylar retinaculum can be presented as triangular or quadrangular and its fibers, with parallel disposition between them, are obliquely attached to the head bundles of the flexor carpi ulnaris muscle. In the results of Grewal et al. (2018) (15), the authors reported 7.5% of "anconeus epitrochlearis" muscles with rectangular conformations, and innervated by the ulnar nerve. With respect to the aponeurosis of the flexor carpi ulnaris muscle (FCU) or Osborne's fascia, eponymic name in honor of orthopedist Geoffrey Vaughan Osborne of Liverpool, England (5), it constitutes part of the coverage or the roof of one of the limits of the proximal ulnar tunnel, also called cubital tunnel (7). Thus, from the complete extension of the ulnar tunnel (composed of three parts) that continues from the epitrochleo-olecranon groove (retrocondylar groove) to the flexor-pronator aponeurosis (deep flexor aponeurosis), the Osborne fascia is present in its 2nd portion as a distal and insensitive extension of the retrocondylar retinaculum (4, 9). The disposition of the fascia, between the heads of the FCU muscle, usually results in a triangular conformation (7). Thus, the fascia reunites the internal margins of the muscle bundles of the FCU muscle heads and can, in special conditions, promote compression of the ulnar nerve and produce a compressive neuritis (7, 8). The Osborne fascia is the result of the fusion and densification of the forearm fascia and the deep fascia of the flexor carpi ulnaris muscle (6, 9). Proximally, the retrocondylar ligament continues in the Struthers' arch, related to the internal brachial ligament and medial intermuscular septum. Distally, these structures continue with the intermuscular septum

hiatus between the flexor digitorum superficialis and flexor carpi ulnaris (FCU) or hiatus of the fascial sheath of the flexor digitorum superficialis (Spinner's ligament), in the third portion of the Ulnar Tunnel. Struthers' ligament, process and supracondylar foramen

**The supracondylar foramen:** (or canal) is an exceptional osteofibrous formation located anteromedially in the distal segment of the humerus, with the participation of the Struthers ligament up to superior to the medial epicondyle and complemented by an acute bone formation (the supracondylar process) (16). Thus, the characteristic supracondylar foramen and its constituent elements (supracondylar process and Struthers ligament), exhibit a medium-distal location in the Brachial Canal (Cruveilhier Canal) with immediate continuity (or of transition) to the medial division of the cubital fossa, at the level of bicapital aponeurosis (lacertus fibrosus or Pirogov's aponeurosis). Regarding the origins, the supracondylar process is characterized as a rudimentary bone heterotopia and is related by homology to those found in mammalian species of "inferior" phylogenetic orders, as in the majority of marsupials and in many of the carnivores, especially in felines, as we can find in the comparative descriptions (10, 17). Thus, we observed, unequivocally, in a comparative bone anatomy study conducted by El-Ghazali & El-Beheri (2018) (18), this process in the humeral bone pattern of the domestic cat (*Felis domestica*) and the foraminal bone formation (supracondylar foramen) with its margins completely ossified and very similar to the human atavistic type. In a publication by Kessel & Rang (1966) (19), the authors considered the Struthers ligament a vestigial and fibrous formation of the atavistic latissimochondiloid muscle (dorsoepitrochlear), an important muscle in climbing mammals, and related to the tendon of the latissimus dorsi muscle. In humans it is represented by a fibrous band located between the triceps brachii muscle and the latissimus dorsi muscle descending from the coracobrachial muscle. Some authors also relate the supracondylar process to the more distal or long insertion of the coracobrachial muscle (10, 20). Caetano et al. (2017) (1) observed an unusual occurrence of insertion very distal from the coracobrachial muscle, although they did not report, in their studies, in this

specimen, a Struthers ligament type conformation and/or a supracondylar process that justified such finding, as is related by Le Double (1897) (10) in his comparative anatomy studies. In humans, the occurrence of the supracondylar process is of the order of 0.6 to 2.7% (17, 21, 22). The supracondylar process is denominated, in different sources, with the following synonyms: supraepitroclear, supracondyloid, supraepicondillary or epicondyle process (10, 17, 24), but the supracondylar foramen (or the supracondylar canal, in a few descriptions) and the Struthers Ligament are not referenced with other denominations. With respect to the eponymic designation of Struthers, we know to be associated with the eminent anatomist of the Victorian period, John Struthers (1823 / 1899). Sir John Struthers was professor of anatomy, comparative anatomy and surgeon in the city of Edinburgh (Scotland), being one of the first anatomists in the United Kingdom to consider, scientifically, the evolutionary theories of Sir Charles Darwin, his contemporary and well-known at the University of Edinburgh, to the repertoire of his anatomical studies (25). The description of this ligament variant, which would later receive his surname, was published, with sufficiency, in an article on the anatomical variations of the upper limb in the year 1854 with a very representative illustration (26). Thus, Struthers (1854) (26) designated the spicular bone process, in the form of a hook, with the denomination of supracondylar and recognized that years before this finding had been reported by himself in a publication in the "Edinburgh Monthly Journal, Oct. 1848" (27). In the text John Struthers mentions the works of Robert Knox (in 1841) and the works of Fridrich Tiedmann (in 1822), regarding bone structure, but it was Struthers who described it (the supracondylar process) in detail and published it. The clinical importance of the supracondylar process resides in the possibility of occurrence of neuropathic and vascular diseases by traumas (at different intensities) of imprisonment and/or related neurovascular compressions of the median nerve and/or the brachial artery - a selectivity of imprisonment may occur, depending on the distribution of the branches of the brachial artery (28, 29, 30). In a study of 380 dry and preserved humers, of Indian origin, reported a very low incidence (of 0.26%) of supracondylar process formation (23). Regarding

the location and disposition of the supracondylar process, the registers indicate it between 5 to 7 cm proximal to the medial epicondyle (17). Shon et al. (2018) (16) reported two surgical cases in which the supracondylar processes presented, in length, 11 and 15 mm of extensions and distant, both, 6 cm from their respective medial epicondyles. The authors also reported, in both conditions, the incarceration of the median nerve, without any affect to the ulnar nerve. Here it is important to say that this bone formation (supracondylar process), and its respective ligament (Struthers' ligament), cannot be confused, despite the eponymic similarity, and relative proximity, with the Struthers' arch, related to the medial head of the triceps brachii muscle and with the medial intermuscular septum together with the passage of the ulnar nerve. Moreover, the supracondylar process and its ligament extension may be related to an anomalous origin or variant of one of the teres pronator muscle heads, which is recognized by different authors (10, 17, 24). In addition, there are differences in the literature with respect to the authors' perceptions of what the Struthers ligament would be. This is common when a characteristic supracondylar process is clearly absent, or when it is rather rudimentary, or in the very intimate associations of the afore mentioned ligament with muscles, making interpretation difficult. Thus, in an important dissection work conducted by Caetano et al. (2017) (1), the authors noted, in 60 limbs, 6 Struthers ligaments related to the high (or very proximal) insertions of the teres pronator muscles. However, the authors did not observe the supracondylar process, according to similar observations by Smith et al. (1973) (21), and Suranyi et al. (1983) (30). In the findings of Dellon (1986), in 104 examined extremities, the authors reported only a rudimentary supracondylar process without the formation of the Struthers ligament (13). (figure 1)

## CONCLUSIONS

The retrocondylar retinaculum (Osborne's ligament) and Struther's ligament are two of the osteofibrous formations relatively under discussed and understood, but of great relevance in the upper limb because they have intimate relations with pathways of important nervous and vascular structures of the antebrachial and brachial segments. These structures

are commonly associated with compressive trauma, causing peripheral neuropathies (sensory and/or motor) related with the ulnar nerve (ulnar tunnel syndrome), the median nerve and correlated vessels. In addition, the ulnar tunnel syndrome has to be differentiated from other neuropathic forms such as those of occurrences by ulnar subluxation or secondary compressions. Thus, this anatomotopographic knowledge, rarely explored in the general anatomy texts, are essential in the differential diagnoses of the various etiologies of imprisonment that affect the upper limb and, especially, for the safe planning of surgical procedures, mitigating the risks of nerves lesions. Another essential point in the knowledge of the osteofibrous formations of the upper limbs is that they are one of the bases for the anthropological research of possibly atavistic remnants of our phylogeny.

## Financing

The authors declare that the work has no funding agencies.

## Interest conflict

The authors declare that there are no conflicts of interest. Work not presented and/or published in other periodicals or proceedings.

## ORCID:

Oliveira, K.M <https://orcid.org/0000-0001-7998-4847>

Meggiolaro, E.D.A <https://orcid.org/0000-0001-8569-1469>

Oliveira, M.F.S <https://orcid.org/0000-0003-2362-3414>

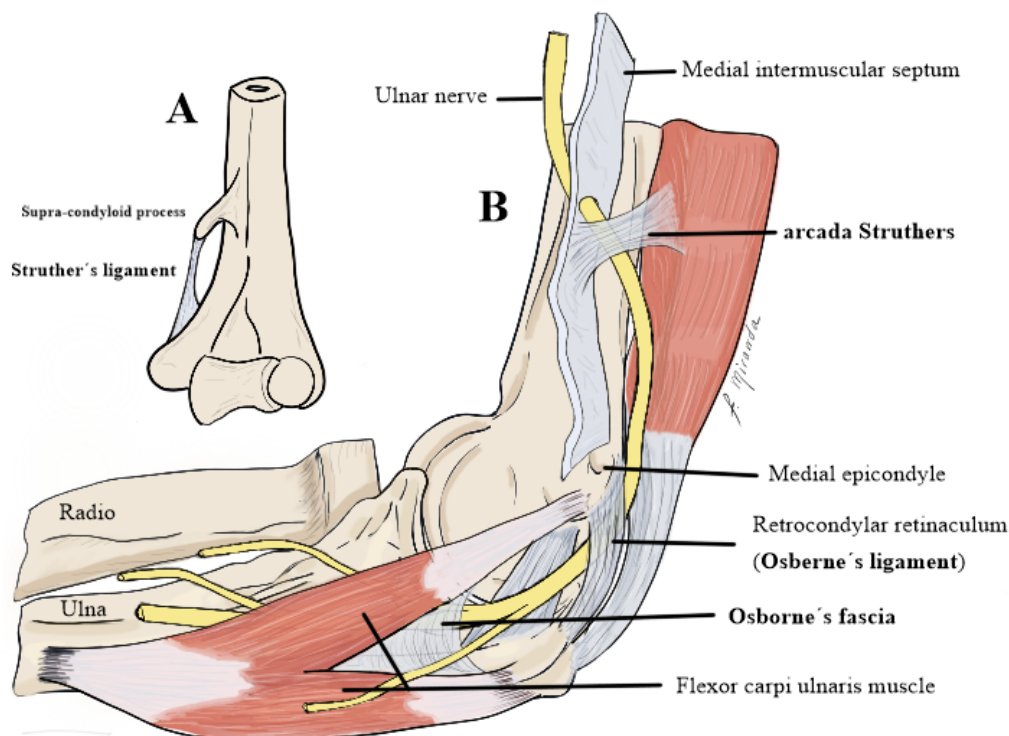
Gonçalves, G.R <https://orcid.org/0000-0002-6486-1729>

Almeida, V.L <https://orcid.org/0000-0002-0604-3074>

Grecco, L.H <https://orcid.org/0000-0001-8896-5859>

Ramos, L.N <https://orcid.org/0000-0002-9834-157X>

Veloso, E.M <https://orcid.org/0000-0003-3553-2931>



**Figure 1:** In “A” the location of the supracondylar ligament and the supracondylar process as originally published in 1854 by John Struther. Image “B”, Image allows differentiation between retrocondylar retinaculum and Osborne’s fascia. Image adapted from Practical Orthopedic Sports Medicine and Arthroscopy 1st Edition

## REFERENCE

- Caetano EB, Sabongi Neto JJ, Vieira LA, Caetano MF, Bona JE, Simonatto TM. Struthers' ligament and supracondylar humeral process: an anatomical study and clinical implications. *Acta Ortop Bras*. 2017 Aug;25(4):137-42. Available from: [https://www.scielo.br/scielo.php?pid=S1413-78522017000400137&script=sci\\_arttext](https://www.scielo.br/scielo.php?pid=S1413-78522017000400137&script=sci_arttext).
- Mizia E, Zarzecki MP, Pekala JR, Baginski A, Kaythampillai LN, Golebiowska M, et al. An anatomical investigation of rare upper limb neuropathies due to the Struthers' ligament or arcade: a meta-analysis. *Folia Morphol*. 2020 May 4. Available from: [https://journals.viamedica.pl/foolia\\_morphologica/article/view/67816](https://journals.viamedica.pl/foolia_morphologica/article/view/67816).
- Spinner RJ, Amadio PC. Compressive neuropathies of the upper extremity. *Clinics in Plastic Surgery*. 2003 Apr;30(2):155-73. Available from: [https://www.plasticsurgery.theclinics.com/article/S0094-1298\(02\)00103-7/abstract](https://www.plasticsurgery.theclinics.com/article/S0094-1298(02)00103-7/abstract).
- Assmus H, Antoniadis G, Bischoff C, Hoffmann R, Martini A, Preißler P, et al. Cubital Tunnel Syndrome – A Review and Management Guidelines. *Cen Eur Neurosurg*. 2011 May;72(02):90-8. Available from: <https://www.thieme-connect.com/products/ejournals/abstract/10.1055/s-0031-1271800>.
- Granger A, Sardi JP, Iwanaga J, Wilson TJ, Yang L, Loukas M, et al. Osborne's Ligament: A Review of its History, Anatomy, and Surgical Importance. *Cureus*. 2017 Mar 6; 9(3), e1080. Available from: <https://www.ncbi.nlm.nih.gov/pmc/articles/PMC5383373/>.
- Mahan MA, Gasco J, Mokhtee DB, Brown JM. Anatomical considerations of fascial release in ulnar nerve transposition: a concept revisited. *JNS*. 2015 Nov;123(5):1216-22. Available from: <https://thejns.org/view/journals/j-neurosurg/123/5/article-p1216.xml>.
- O'Driscoll S, Horii E, Carmichael S, Morrey B. The cubital tunnel and ulnar neuropathy. *The Journal of Bone and Joint Surgery British volume*. 1991 Jul;73-B(4):613-7. Available from: <https://online.boneandjoint.org.uk/doi/abs/10.1302/0301-620x.73b4.2071645>.
- Osborne G. Compression Neuritis of the Ulnar Nerve at the Elbow. *Hand*. 1970 Feb;2(1):10-3. Available from: <https://journals.sagepub.com/doi/abs/10.1016/0072-968X%2870%2990027-6?journalCode=jhsa>.
- Polatsch DB, Melone CP, Beldner S, Incorvaia A. Ulnar Nerve Anatomy. *Hand Clinics*. 2007 Aug;23(3):283-9. Available from: <https://www.sciencedirect.com/science/article/abs/pii/S0749071207000534>.
- Le Double AF. *Traité des variations du système musculaire de l'homme: et de leur signification au point de vue de l'anthropologie zoologique*. Schleicher frères. Librairie C Reinwald: Paris; 1897.
- Testut L. *Traité d'anatomie humaine: anatomie descriptive, histologie, développement* (Vol. 3). O. Doin. 1893.
- Tubbs RS, Shoja MM, Loukas M, Bergman's comprehensive encyclopedia of human anatomic variation. John Wiley & Sons. 2016. Available from: <https://books.google.com.br/books?hl=pt-BR&lr=&id=6h1EDQAAQBAJ&oi=fnd&pg=PA130&dq=Bergman%27s+comprehensive+encyclopedia+of+human+anatomic+variation&ots=HHKDpj6qiP&sig=FQLwAZ1E#v=onepage&q=Bergman%20comprehensive%20encyclopedia%20of%20human%20anatomic%20variation&f=false>.
- Dellon AL. Musculotendinous variations about the medial humeral epicondyle. *The Journal of Hand Surgery: Journal of the British Society for Surgery of the Hand*. 1986 Jun;11(2):175-81. Available from: <https://www.sciencedirect.com/science/article/abs/pii/0266768186902548>.
- Cheriyian T, Neuhaus V, Mudgal, CS. Velocity drop in anconeus epitrochlearis-associated cubital tunnel syndrome. *Am J Orthop*. 2014 May;43(5):227-9. Available from: <https://mdedge-files-live.s3.us-east-2.amazonaws.com/files/s3fs-public/Document/September-2017/043050227.pdf>.
- Grewal SS, Collin P, Ishak B, Iwanaga J, Amrami KK, Ringler MD, et al. Innervation of the anconeus epitrochlearis muscle: MRI and cadaveric studies. *Clin Anat*. 2019 Mar;32(2):218-23. Available from: <https://onlinelibrary.wiley.com/doi/abs/10.1002/ca.23285>.
- Shon H, Park J, Kim D, Kang S, Kim K, Hong S. Supracondylar process syndrome: two cases of median nerve neuropathy due to compression by the ligament of Struthers. *JPR*. 2018 Apr;Volume 11:803-7. Available from: <https://www.ncbi.nlm.nih.gov/pmc/articles/PMC5907893/>.
- Newman A. The supracondylar process and its fracture. *American Journal of Roentgenology*. 1969 Apr;105(4):844-9. Available from: <https://www.ajronline.org/doi/pdf/10.2214/ajr.105.4.844>.
- El-Ghazali HM, El-behery EI. Comparative macro-anatomical observations of the appendicular skeleton of New Zealand rabbit (*Oryctolagus cuniculus*) and domestic cat (*Felis domestica*) thoracic limb. *Inter J Vet Sci*. 2018;7(3):127-33. Available from: <http://www.ijvets.com/pdf-files/Volume-7-no-3-2018/127-133.pdf>.
- Kessel L, Rang M. Supracondylar Spur of the Humerus. *The Journal of Bone and Joint Surgery British volume*. 1966 Nov;48-B(4):765-9. Available from: <https://online.boneandjoint.org.uk/doi/abs/10.1302/0301-620x.48b4.765>.
- Rajeshwari Devi RR, Shah HR, Trivedi DJ. Accessory Head of Coracobrachialis and its Clinical Uses. *IJAR*. 2019 Jan 31;7(1):864-7. Available from: [http://www.journalijar.com/uploads/14\\_IJAR-26022.pdf](http://www.journalijar.com/uploads/14_IJAR-26022.pdf)
- Smith RV, Fisher RG. Struthers ligament: a source of median nerve compression above the elbow. *Journal of Neurosurgery*. 1973 Jun;38(6):778-9. Available from: <https://thejns.org/view/journals/j-neurosurg/38/6/article-p778.xml>.
- Suresh SS. Fracture of supracondylar process of the humerus. *Sultan Qaboos Univ Med J*. 2008 Jul;8(2):223-5. Available from: <https://www.ncbi.nlm.nih.gov/pmc/articles/PMC3074825/>.
- Kumar GR, Mehta CD. A study of the incidence of supracondylar process of the humerus. *J Anat Soc India*. 2008;57:111-5.
- Pikula JR. Supracondylar process of the humerus: a case report. *The Journal of the Canadian Chiropractic Association*. 1994 Dec;38(4): 211-5. Available from: <https://www.ncbi.nlm.nih.gov/pmc/articles/PMC2485005/>.
- Loukas M, Pennell C, Tubbs RS, Cohen-Gadol AA. Sir John Struthers (1823–1899) and His Ligament and Arcade. *Neurosurgery*. 2010 Jun 1;66(6):1170-3. Available from: <https://academic.oup.com/neurosurgery/article-abstract/66/6/1170/2556843>.
- Struthers J. On Some Points in the Abnormal Anatomy of the Arm. *Br Foreign Med Chir Rev*. 1854 Apr;13(26):523-33. Available from: <https://www.ncbi.nlm.nih.gov/pmc/articles/PMC5185442/>.
- Struthers J. On a Peculiarity of the Humerus and Humeral Artery. *J Hand Surg Eur Vol*. 2007 Feb;32(1):54-6. Available from: <https://journals.sagepub.com/doi/10.1016/j.jhsb.2006.09.001>.
- Lordan J, Rauh P, Spinner RJ. The clinical anatomy of the supracondylar spur and the ligament of Struthers. *Clin Anat*. 2005 Oct;18(7):548-51. Available from: <https://onlinelibrary.wiley.com/doi/abs/10.1002/ca.20132>.
- Meda N, Verma H, Tripathi RK. Ischemic brachial artery entrapment syndrome by supracondylar humeral bony spur. *Journal of Vascular Surgery Cases*. 2015 Jun;1(2):116-9. Available from: <https://www.sciencedirect.com/science/article/pii/S2352667X1500034X>.
- Suranyi L. Median nerve compression by Struthers ligament. *Journal of Neurology, Neurosurgery & Psychiatry*. 1983 Nov 1;46(11):1047-9. Available from: <https://jnnp.bmj.com/content/46/11/1047.short>.